



PATIENT
Chance McConnehey

PRESENTING CLINICAL SIGNS

History: Grade III murmur, asymptomatic. Assess prior to anesthesia.
Current medications: Clindamycin, Carprovet

SPECIES
Canine

ECHOCARDIOGRAM FINDINGS

2D, m-mode, color flow and Doppler imaging is available.

Left ventricle: The LV diameter is normal with adequate myocardial function. LV wall thicknesses are normal.

BREED
Bichon Poodle Mix

Left atrium: The left atrium is mildly dilated.

Mitral valve: The mitral valve is diffusely thickened with no prolapse into the left atrial lumen. Mild to moderate eccentric mitral regurgitation with a normal velocity.

SEX
Male Neutered

Aortic valve/aorta: The aortic valve is normal in morphology and mobility. Normal aortic outflow velocity; laminar flow. No aortic insufficiency.

AGE
7 years

Right ventricle: Normal right ventricular diameter and morphology indicating no overt evidence of pulmonary arterial hypertension.

Right atrium: Normal RA dimension.

Tricuspid valve: The tricuspid valve appears normal with trace tricuspid regurgitation; normal velocity.

WEIGHT
14.6lbs

Pulmonic valve/pulmonary artery: The pulmonic valve is normal in morphology and mobility. No pulmonic insufficiency. Normal RVOT velocity; laminar flow.

Pericardium/other: No pericardial or pleural effusion noted. No obvious cardiac masses.

Heart rhythm: ECG reveals a sinus rhythm with an average HR of 150bpm.

INTERPRETED BY

Maggie Machen
Lamy, DVM
DACVIM (Cardiology)

2-Dimensional Measurements

Ao diam (cm)	1.6
LA diam (cm)	1.96
LA:Ao (Swe)	1.4
IVS thickness (cm)	0.64
LVID diastole (cm)	2.6
PW thickness (cm)	0.68
LVID systole (cm)	1.3
FS (%)	50

Doppler Measurements

PV Vmax (m/s)	0.94
AoV Vmax (m/s)	1.6
MR Vmax (m/s)	6.3
TR Vmax (m/s)	2.7
TR PG (mmHg)	30

IMAGING PERFORMED BY

Pamela Harrigan,
RDCS

INTERPRETATION OF THE FINDINGS

The cause of the murmur is chronic degenerative valve disease causing mild to moderate mitral and trace tricuspid regurgitation. Lack of significant left atrial enlargement indicates the current risk for complication is low. No concurrent issues such as systolic dysfunction or pulmonary hypertension are noted in this study. Assessment of progression in the future will help predict long term prognosis, which is highly variable at this stage (B1).

HOSPITAL NAME

Airport Animal
Hospital

REFERRING VET

Dr. Gudluru

RECOMMENDATIONS

- In an asymptomatic dog without significant left atrial enlargement, no cardiac medications are clearly indicated.
- Omega fatty acid supplementation and mild salt restriction may be of some long term benefit.
- Anesthetic risk is considered mild if needed. Cardiac protective drug choices (opioid/benzodiazepine premedication, propofol or alfaxalone induction, isoflurane gas) are recommended. Pre-oxygenate for 5-10 minutes prior to induction. Monitor

INVOICE
24085

DATE
5/8/22



PATIENT

Chance McConnehey

for arrhythmias, hypotension, and hypoxia both intra and post-operatively and intervene as necessary. Mild IV fluid restriction is recommended to avoid fluid overload. Avoid heart rate stimulating drugs such as atropine unless clinically indicated.

SPECIES

Canine

- Monitor for development of a cough, labored breathing, exercise intolerance or collapse episodes.

BREED

Bichon Poodle Mix

PLAN

- Recommend conservative monitoring with a recheck echocardiogram in 6 months, sooner if any development of clinical signs.

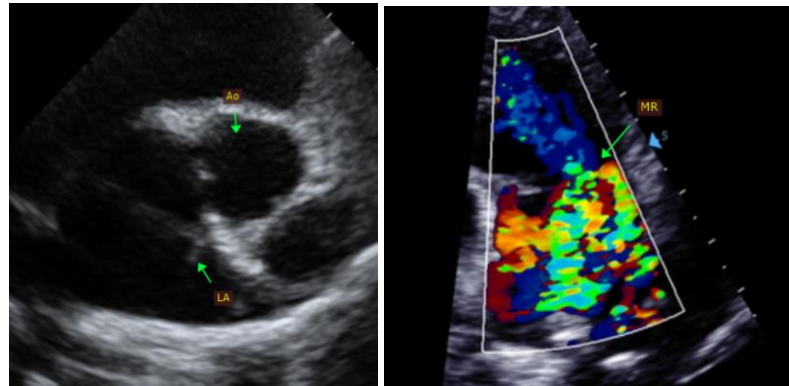
SEX

Male Neutered

IMAGES

AGE

7 years



WEIGHT

14.6lbs

INTERPRETED BY

Maggie Machen
 Lamy, DVM
 DACVIM (Cardiology)

The information and recommendations provided are based on the images presented by the referring veterinarian. No evaluation can be communicated regarding pathology that was not visible in the image/video clips provided.

IMAGING PERFORMED BY

Pamela Harrigan,
 RDCS

Thank you for this referral. If the clinical or image interpretation does not parallel your findings or if I can be of any further assistance please contact me.

Maggie Machen Lamy, DVM
 Diplomate of the American College of Veterinary Internal Medicine (Cardiology)
 info@sonopath.com

HOSPITAL NAME

Airport Animal
 Hospital

REFERRING VET

Dr. Gudluru

INVOICE

24085

DATE

5/8/22